Author's Accepted Manuscript

www.elsevier.com

Diagnostic Value of Non-invasive Computed Tomography Perfusion Imaging and Coronary computed tomography angiography for Assessing Hemodynamically Significant Native Coronary Artery Lesion: A Meta-Analysis

Pooja Sethi, Hemang B. Panchal, Sreenivas P. Veeranki, Zia Ur Rahman, Hadii Mamudu, Timir K. Paul

PII: S0002-9629(17)30141-6
DOI: http://dx.doi.org/10.1016/j.amjms.2017.03.016
Reference: AMJMS412

To appear in: *The American Journal of the Medical Sciences*

Cite this article as: Pooja Sethi, Hemang B. Panchal, Sreenivas P. Veeranki, Zia Ur Rahman, Hadii Mamudu and Timir K. Paul, Diagnostic Value of Non-invasive Computed Tomography Perfusion Imaging and Coronary computed tomography angiography for Assessing Hemodynamically Significant Native Coronary Artery Lesion: A Meta-Analysis, *The American Journal of the Medical Sciences,* http://dx.doi.org/10.1016/j.amjms.2017.03.016

Diagnostic Value of Non-invasive Computed Tomography Perfusion Imaging and Coronary computed tomography angiography for Assessing Hemodynamically Significant Native Coronary Artery Lesion: A Meta-Analysis

Pooja Sethi, MD
Cardiology Fellow
Department of Internal Medicine
East Tennessee State University
Johnson City, TN
Email: sethip@estu.edu

Hemang B. Panchal, MD, MPH
Cardiology fellow
Department of Internal Medicine
East Tennessee State University Johnson City, TN
Email: hemangbpanchal@gmail.com

Sreenivas P. Veeranki, MBBS, Dr.PH
Biostatistician Division of Epidemiology
Department of Preventive Medicine and Community Health
University of Texas Medical Branch
Galveston, TX Email: drveeranki@gmail.com

Zia Ur Rahman, MD,
Resident Physician
Department of Internal Medicine
East Tennessee State University
Johnson City, TN
Email: Rahman@mail.etsu.edu

Hadii Mamudu, PhD
Associate Professor
Department of Health Services Management and Policy
College of Public Health
East Tennessee State University
mamudu@etsu.edu

Timir K Paul, MD, PhD
Assistant Professor,
Director, Cardiovascular Research
Division of Cardiology, Department of Internal Medicine
East Tennessee State University
Johnson City, TN
Email: pault@etsu.edu

Corresponding author:
Timir K Paul, MD, PhD
Assistant Professor,
Division of Cardiology, Department of Internal Medicine
East Tennessee State University
Johnson City, TN
Email: pault@etsu.edu
Phone: 423-979-4100, Fax: 423-979-4134

Conflict of interest:

None

Key words:

Computed tomography angiography, coronary artery lesion, diagnostic accuracy, Computed tomography perfusion, fractional flow reserve

Source of Funding

None

Short Title

Diagnostic Value of CTA+CTP

Abstract

BACKGROUND

Coronary computed tomography angiography (CTA) is an established noninvasive imaging modality for diagnosis of coronary artery disease. Computed tomography perfusion (CTP) imaging is an emerging non-invasive method for detecting myocardial ischemia. Combined CTA with CTP provides a more comprehensive non-invasive evaluation of patients with intermediate coronary artery lesions.

OBJECTIVE

To determine the diagnostic performance of CTP with and without CTA in assessment of hemodynamically significant coronary artery lesions in comparison to invasive fractional flow reserve (FFR).

METHODS

PubMed and the Cochrane Center Register of Controlled Trials were searched from January 2010 through December 2015. Nine original studies evaluating the diagnostic performance of CTP with and without CTA to invasive coronary angiography in assessment of hemodynamic significance of coronary lesions were selected for this study. Sensitivity, specificity, positive and negative likelihood ratios (LR+ and LR-, respectively) and diagnostic odds ratio (DOR) were calculated.

RESULTS

A total of 543 vessels were evaluated with CTA+CTP and the sensitivity, specificity, LR+ and LR- and DOR were 0.85 [95% confidence interval (CI: 0.79-0.89)] 0.94 (CI: 0.91-0.97), 15.8 (CI: 7.99-31.39), 0.146 (CI: 0.08-0.26), and 147.2 (CI: 69.77-310.66). Summary Receiver Operating Characteristics (SROC) results showed area under the curve (AUC) of 0.97 indicating

that CTA+CTP may detect hemodynamically significant coronary artery lesions with high accuracy. A total of 676 vessels were evaluated with CTP alone and the sensitivity, specificity, LR+ and LR- and DOR were 0.83 (CI: 0.78-0.87), 0.84 (CI: 0.80-0.87) 5.26 (CI: 2.93-9.43), 0.209 (CI: 0.12-0.36), and 31.97 (CI: 11.59-88.20). The sensitivity, specificity, LR+ and LR- and DOR of CTA alone (860 vessels) were 0.90 (CI: 0.87-0.93), 0.72 (CI: 0.68-0.75), 3.27 (CI: 2.46-4.36), 0.122 (0.06-0.23), and 29.61 (CI: 15.62-56.12).

CONCLUSION

The results of this meta-analysis suggest that adding CTP to CTA significantly improves diagnostic performance of hemodynamic significance of coronary artery lesions compared to CTA alone. CTA with CTP is closely comparable with invasive FFR and is a feasible non-invasive method to assess hemodynamic significance of coronary lesions in patients with stable coronary artery disease.

Key words:

Computed tomography angiography, coronary artery lesion, diagnostic accuracy, Computed tomography perfusion, fractional flow reserve

Introduction:

Assessment of Fractional Flow Reserve (FFR) in addition to anatomic evaluation by invasive coronary angiography is considered as the gold standard for assessment of hemodynamic significance of coronary artery lesions, facilitating clinical decision making regarding coronary artery revascularization.[1] Computed tomography angiography (CTA) of coronary artery is a non-invasive method for anatomic evaluation of severity of coronary artery lesion[2]. Newly introduced computed tomography perfusion (CTP) imaging is an emerging noninvasive method that allows quantitative assessment of myocardial blood flow index [2] for detecting myocardial ischemia. Severity of stenosis assessed by CTA may not correlate with the functional significance of coronary artery lesions, particularly in intermediate risk lesions (50-70% stenosis). CTP provides a good estimate of the functional significance of coronary lesions[2]. Combined CTA with CTP provides a more comprehensive non-invasive evaluation of intermediate coronary artery lesion. Several studies have evaluated diagnostic accuracy of CTA+CTP compared to invasive FFR[1,3,4,6-10] , but have been limited due to small sample size. The objective of our meta-analysis is to determine the diagnostic performance of CTP with and without CTA in assessment of hemodynamically significant coronary artery lesions in comparison to invasive FFR in patients with stable coronary artery stenosis.

Methods

This meta-analysis was performed in accordance with Meta-Analysis of Observational Studies in Epidemiology7 statements. General guidelines of Cochrane Handbook for Systematic Reviews of Interventions, version 5.1.0 were used in developing methodology and meta-analysis was conducted in adherence to these guidelines. We searched the National Library of Medicine, PubMed, National Institute of Health clinical trials registry and the Cochrane Central Register of Controlled Trials to include clinical studies that assessed diagnostic performance of non-invasive CTA and CTP in comparison to invasive FFR in diagnosing hemodynamically significant coronary artery lesion. Studies were included if conducted during the period of January 2000 through December 2015. The key words used for searching studies were "computed tomography angiography", "fractional flow reserve", "Computed Tomography Perfusion", "CTA", "CTP", "FFR", "diagnostic accuracy", "diagnostic performance" and "coronary artery lesion". In addition to our computerized search, we manually reviewed the reference lists and related articles of all retrieved studies to complete our search. Three independent authors (PS, HBP and ZR) reviewed all titles from the search results and articles were selected for final data extraction.

Inclusion and Exclusion Criteria:

To be selected for analysis, a study had to meet the following inclusion criteria:

(1) Study compares diagnostic performance of CTP with and without CTA to invasive FFR.

(2) Study reports (a) true positive, false positive, true negative and false negative outcomes or b) sensitivity, specificity, positive predictive value (PPV) and negative predictive value (NPV) with

enough information to calculate true positive, false positive, true negative and false negative outcomes. A total of 76 studies for CTA and CTP were identified. 60 studies were non relevant and were therefore excluded. 17 potentially relevant studies were screened for retrieval. 7 studies did not meet inclusion criteria and therefore a total of 10 studies were included in the meta-analysis.

Data Extraction:

After identifying all relevant articles, data from each study including patient demographics, type and number of coronary vessels evaluated, time between CTA, CTP and angiographic images, blinding information on FFR and CTA and CTP readings were extracted. End points were true positive, false positive, true negative and false negative values for CTA, CTP and FFR. End point data from CTA were extracted and included in our analysis only if studies have provided data on anatomically significant coronary artery stenosis of ≥50% on CTA. Three reviewers (PS, HBP and ZR) independently extracted data and assessed outcomes. The inter-rater agreement was 90%, and disagreements were resolved by consensus and in discussion with senior author (TP).

Statistical Analysis:

SAS software, version 9.3 (SAS Institute Inc., Cary, NC) and Meta-Disc software, version 1.4 (XI Cochrane Colloquium) were used to conduct all analyses. Sensitivity, specificity, positive likelihood ratio (LR+), negative likelihood ratio (LR-) and diagnostic odds ratio (DOR) were computed using bivariate meta-analysis models. The sensitivity and specificity of each study were used to plot the summary receiver operator characteristics (SROC) and area under the

SROC curve (AUC) was calculated. Heterogeneity between the studies was evaluated using Q test and I^2 statistics. Random effects model was applied when $P < 0.10$ for Q test or I^2 value >50%, indicating substantial heterogeneity. In addition, explanation of heterogeneity by threshold effect was verified using the Spearman correlation approach. P value <0.05 was considered significant for statistical inferences.

RESULTS:

Eight and six studies fulfilled the inclusion criteria for per vessel analysis of CTA [1-4, 6-9] and CTP [1-6] respectively. Six studies met inclusion criteria for per vessel CTA+CTP analysis[1, 4, 6-9]. Seven, four, and six studies met inclusion criteria for per patient CTA[1-3, 7-10], CTP [1-3, 10,] CTA+ CTP[1, 3, 7-10] respectively. Studies overview, baseline patient characteristics, and study quality assessment were included in **Table 1**.

Per-vessel analysis:

A total of 543 vessels were evaluated with CTA+CTP. The pooled sensitivity, specificity, LR+, LR- and DOR were 0.85 (Confidence interval [CI]: 0.79-0.89), 0.94 (CI: 0.91-0.96), 15.8 (CI:7.99-31.39) and 0.146 (CI:0.08-0.27), 147.2 (CI:69.77-310.66) respectively. SROC results showed AUC of 0.97 indicating that CTA+CTP may detect hemodynamically significant coronary artery lesions with high accuracy **(Figure 3)**.

The sensitivity, specificity, LR+, LR- and DOR for CTP alone (676 vessels) were 0.83 (CI: 0.77-0.87), 0.84 (CI: 0.80-0.87) 5.26 (CI:2.93-9.44), 0.209 (CI: 0.12-0.36) and 31.97 (CI: 11.59-88.20) and for CTA alone (860 vessels) were 0.91 (CI: 0.87-0.93), 0.72 (CI: 0.68-0.76), 3.28 (CI: 2.46-4.36) , 0.12 (CI: 0.06-0.23) and 29.61 (CI: 15.62-56.12). SROC results showed AUC of 0.92 for CTP alone (**Figure 2**) and 0.87 for CTA alone (**Figure 1**) indicating that CTP

or CTA alone is less accurate, compared to CTA+CTP in detecting hemodynamically significant coronary artery lesions.

Per–patient analysis

A total of 322 patients were evaluated with CTA+CTP. The pooled sensitivity, specificity, LR+ and LR- , and DOR were 0.92 (CI: 0.87-0.96), 0.85 (CI: 0.79-0.90) 5.03 (CI: 3.36-7.54) and 0.117 (CI: 0.07-0.20), 45.50 (CI: 21.30-97.18) respectively. SROC results showed AUC of 0.94 indicating that CTA+CTP may detect hemodynamically significant coronary artery lesions with high accuracy.

A total of 304 patients were evaluated by CTP alone. The sensitivity, specificity, LR+ and LR-, DOR were 0.81 (CI: 0.72-0.87) 0.79 (CI: 0.72-0.85), 3.74 (CI: 1.45-9.60) 0.263 (CI: 0.13-0.53), and 20.10 (CI: 4.90-82.63) respectively. The sensitivity, specificity, LR+ and LR- and DOR for CTA alone (403 vessels) were 0.92 (CI: 0.87-0.95), 0.66 (CI: 0.59-0.72), 2.25 (CI: 1.56-3.26) and 0.144 (CI: 0.05-0.38), 16.17 (CI: 5.65-46.30) respectively. SROC results showed AUC of 0.88 for CTP alone and 0.78 for CTA alone indicating that CTP or CTA alone is less accurate compared to CTA+CTP in detecting hemodynamically significant coronary artery lesions

DISCUSSION:

Despite major advancements in the field of cardiovascular medicine, cardiovascular events remain a major cause of mortality and morbidity worldwide [11]. The risk stratification is very important in managing patients with coronary artery disease (CAD). Current guidelines recommend risk factors modification for patients with low risk of pretest probability for CAD and noninvasive imaging for patients with intermediate pretest probability[12]. Non Invasive

imaging can be performed with CTA for anatomic assessment of coronary vessels and/or with CTP for a physiologic assessment. Both of these tests have some limitations in diagnostic accuracy[13]. Until now, the gold standard test for further evaluation of intermediate lesion is invasive coronary angiography with FFR measurement[14, 15], which is associated with risk of complications. We can potentially avoid these risks if non-invasive tests such as CTP with or without CTA would risk stratify with high accuracy in patients with intermediate pretest probability for CAD. [16.] Recent advances in the field of cardiology has made it possible for us to re-risk stratify these patients noninvasively with combined anatomical and physiological tests (CTA and CTP). Our study demonstrated that combined CTA and CTP provide better diagnostic performance for evaluation of hemodynamically significant coronary artery lesions. A recent multicenter study (CORE 320)[17] showed that combined CTA and CTP have similar prediction of major adverse cardiac events over 2 years when compared with invasive coronary angiography and single photon emission computed tomography (SPECT). Another study showed the incremental value of CTP to CTA in evaluating functionally significant coronary artery stenosis[18]. Van Rosendael et al. demonstrated that CTP has a promising value when added to CTA in assessment of coronary artery stenosis[19]. Study (CARS 320) [20] investigated the value of CTP and CTA in diagnosis of coronary artery restenosis comparing with coronary angiography revealing that combined coronary CTA and CTP improve the diagnostic accuracy of coronary artery stenosis and diagnosing in-stent restenosis as compared with CTA alone[20]. Another study compared both CTA and CTP to cardiac magnetic resonance perfusion imaging in detecting CAD and concluded that the combination of CTA and CTP had similar accuracy in detecting significant CAD when compared to CMR perfusion imaging[21]. George et al. found CTP imaging is a better predictor of myocardial ischemia when used in conjunction with CTA imaging [21]. A

study by Stefanini et al. demonstrated that CTA was a good test for patients with high pretest probability of CAD; however, it was still inferior to invasive coronary angiography, thus limiting its role in the assessment of intermediate risk patients [13]. Recent studies have shown that the addition of FFR-CT to CTA may yield comprehensive structural and functional assessment of CAD[22-24]. A recent meta-analysis studied the value of adding CTP and CT-FFR to CTA in assessment of significant CAD and concluded that the addition of these 2 modalities increases the specificity of CTA in determining functionally significant CAD as determined by invasive coronary angiography[25.]

The results of our study demonstrate that CTA + CTP has very low LR- and therefore if the test is negative, obstructive CAD can be ruled out and the patient with intermediate risk for CAD can be risk stratified to low risk category. With negative CTA + CTP test, further assessment of CAD with invasive coronary angiogram can be avoided unless high clinical suspicious of obstructive CAD. Additionally, the results of this study demonstrate that CTA + CTP has very high LR+ and therefore if the test is positive, obstructive CAD should be strongly considered and the patient with intermediate risk for CAD can be risk stratified to higher risk category. With positive CTA + CTP test, further assessment of CAD with invasive coronary angiogram should be performed. The results suggest that combined CTA +CTP are highly comparable to invasive coronary angiography with FFR.

Our meta-analysis has several limitations. Because of the meta-analytic nature of this study, we were unable to evaluate the effects of gender, race, and ethnic background on the measured outcomes. In addition, there is a potential for publication bias. Most of the baseline studies had limited sample size. Power analysis was not performed in these studies. The time between CT

imaging and invasive coronary angiography varied between studies. This time interval was long in some of the studies; up to 3 months; during which the coronary artery lesion severity may have changed. Our meta-analysis excluded the studies evaluating diagnostic performance of CTA and CTP in patients who underwent coronary artery revascularization with either stent placement or coronary artery bypass graft due to limited references. We were unable to measure the implication of diagnostic performance of CTA and CTP on clinical outcomes of patients because it was not studied in any study included in our meta-analysis.

We believe that addition of CTP to CTA may improve diagnostic performance of non-invasive CTA to evaluate hemodynamically significant coronary artery lesions and may improve clinical decision making to decide the need for coronary artery revascularization. Combined CTA and CTP may be used to defer an invasive study in evaluation of stable CAD unless clinical suspicion indicates otherwise.

Conclusion:

The results of this meta-analysis suggest that adding CTP to CTA significantly improves diagnostic performance of hemodynamic significance of coronary artery lesions compared to CTA alone. CTA with CTP is closely comparable with invasive FFR and is a feasible non-invasive method to assess hemodynamic significance of coronary lesions in patients with stable CAD.

References

[1] Ko BS, Cameron JD, Leung M, Meredith IT, Leong DP, Antonis PR, Crossett M, Troupis J, Harper R, Malaiapan Y, Seneviratne SK (2012) Combined CT coronary angiography and stress myocardial perfusion imaging for hemodynamically significant stenoses in patients with suspected coronary artery disease: a comparison with fractional flow reserve. JACC Cardiovasc Imaging 5 (11):1097-1111.

[2] Rossi A, Dharampal A, Wragg A, Davies LC, van Geuns RJ, Anagnostopoulos C, Klotz E, Kitslaar P, Broersen A, Mathur A, Nieman K (2014) Diagnostic performance of hyperaemic myocardial blood flow index obtained by dynamic computed tomography: does it predict functionally significant coronary lesions?. Eur Heart J Cardiovasc Imaging 15 (1):85-94.

[3] Bettencourt N, Ferreira ND, Leite D, Carvalho M, da Silva Ferreira W, Schuster A, Chiribiri A, Leite-Moreira A, Silva-Cardoso J, Nagel E, Gama V (2013) CAD detection in patients with intermediate-high pre-test probability: low-dose CT delayed enhancement detects ischemic myocardial scar with moderate accuracy but does not improve performance of a stress-rest CT perfusion protocol. JACC Cardiovasc Imaging 6(10):1062-1071.

[4] Choo KS, Hwangbo L, Kim JH, Park YH, Kim JS, Kim J, Chun KJ, Jeong DW, Lim SJ (2013) Adenosine-stress low-dose single-scan CT myocardial perfusion imaging using a 128-slice dual-source CT: a comparison with fractional flow reserve. Acta Radiol 54 (4):389-395.

[5] Kono AK, Coenen A, Lubbers M, Kurata A, Rossi A, Dharampal A, Dijkshoorn M, van Geuns RJ, Krestin GP, Nieman K (2014) Relative myocardial blood flow by dynamic computed tomographic perfusion imaging predicts hemodynamic significance of coronary stenosis better than absolute blood flow. Invest Radiol 49 (12):801-807.

[6] Ko BS, Cameron JD, Meredith IT, Leung M, Antonis PR, Nasis A, Crossett M, Hope SA, Lehman SJ, Troupis J, DeFrance T, Seneviratne SK (2012) Computed tomography stress myocardial perfusion imaging in patients considered for revascularization: a comparison with fractional flow reserve. Eur Heart J 33(1):67-77

[7] Nasis A, Ko BS, Leung MC, Antonis PR, Nandurkar D, Wong DT, Kyi L, Cameron JD, Troupis JM, Meredith IT, Seneviratne SK (2013) Diagnostic accuracy of combined coronary angiography and adenosine stress myocardial perfusion imaging using 320-detector computed tomography: pilot study. Eur Radiol 23 (7):1812-1821.

[8] Kim SM, Choi JH, Chang SA, Choe YH (2013) Additional value of adenosine-stress dynamic CT myocardial perfusion imaging in the reclassification of severity of coronary artery stenosis at coronary CT angiography. Clin Radiol 68 (12):e659-668.

[9] Bamberg F, Becker A, Schwarz F, Marcus RP, Greif M, von Ziegler F, Blankstein R, Hoffmann U, Sommer WH, Hoffmann VS, Johnson TR, Becker HC, Wintersperger BJ, Reiser MF, Nikolaou K (2011) Detection of hemodynamically significant coronary artery stenosis: incremental diagnostic value of dynamic CT-based myocardial perfusion imaging. Radiology 260 (3):689-698.

[10] Rief M, Zimmermann E, Stenzel F, Martus P, Stangl K, Greupner J, Knebel F, Kranz A, Schlattmann P, Laule M, Dewey M (2013) Computed tomography angiography and myocardial computed tomography perfusion in patients with coronary stents: prospective intraindividual comparison with conventional coronary angiography. J Am Coll Cardiol 62 (16):1476-1485.

[11] Global Status Report on Non Communicable Diseases 2010. World Health Organization, Geneva; 2010. http://www.who.int/nmh/publications/ncd_report_full_en.pdf. Date Accessed; 2/16/2015.

[12] Qaseem A, Fihn SD, Dallas P, Williams S, Owens DK, Shekelle P (2012) Management of stable ischemic heart disease: summary of a clinical practice guideline from the American College of Physicians/American College of Cardiology Foundation/American Heart Association/American Association for Thoracic Surgery/Preventive Cardiovascular Nurses Association/Society of Thoracic Surgeons. Ann Intern Med 157 (10):735-743.

[13] Stefanini GG, Windecker S (2015) Can coronary computed tomography angiography replace invasive angiography? Coronary computed tomography angiography cannot replace invasive angiography. Circulation 131 (4):418-425.

[14] Almeida J, Fonseca P, Dias T, Ladeiras-Lopes R, Bettencourt N, Ribeiro J, Gama V (2016) Comparison of Coronary Artery Disease Consortium 1 and 2 Scores and Duke Clinical Score to Predict Obstructive Coronary Disease by Invasive Coronary Angiography. Clin Cardiol 39(4):223-228

[15] Groves EM, Seto AH, Kern MJ (2016) Invasive testing for coronary artery disease: FFR, IVUS, OCT, NIRS. Heart Failure Clin 12(1):83-95.

[16] Carrascosa PM, Deviggiano A, Capunay C, Campisi R, de Munain ML, Vallejos J, Tajer C, Rodriguez-Granillo GA (2015) Incremental value of myocardial perfusion over coronary angiography by spectral computed tomography in patients with intermediate to high likelihood of coronary artery disease. Eur J Radiol 84 (4):637-642.

[17] Chen MY, Rochitte CE, Arbab-Zadeh A, Dewey M, George RT, Miller JM, Niinuma H, Yoshioka K, Kitagawa K, Nakamori S, Laham R (2015) Prognostic Value of Combined CT Angiography and Myocardial Perfusion Imaging vs. Invasive Coronary Angiography and Nuclear Stress Perfusion Imaging for Predicting Major Adverse Cardiovascular Events-The CORE320 Multicenter Study. Circulation 132 (Suppl 3): A16903.

[18] Linde JJ, Kuhl JT, Hove JD, Soergaard M, Kelbaek H, Jensen GB, Nielsen WB, Kofoed KF (2013) Myocardial CT perfusion imaging improves diagnostic accuracy of coronary CT angiography especially in patients with intermediate severity coronary artery stenoses. Eur Heart J 34 (suppl 1): P4703.

[19] Van Rosendael AR, de Graaf MA, Scholte AJ (2015) Myocardial CT perfusion for the prediction of obstructive coronary artery disease, valuable or not? Cardiovasc Diagn and Ther 5(1):63-66

[20] Bettencourt N, Chiribiri A, Schuster A, Ferreira N, Sampaio F, Pires-Morais G, Santos L, Melica B, Rodrigues A, Braga P, Azevedo L, Teixeira M, Leite-Moreira A, Silva Cardoso J, Nagel E, Gama V (2013) Direct comparison of cardiac magnetic resonance and multidetector computed tomography stress-rest perfusion imaging for detection of coronary artery disease. J Am Coll Cardiol 61(10):1099-1107.

[21] George RT, Arbab-Zadeh A, Miller JM, Vavere AL, Bengel FM, Lardo AC, Lima JA (2012) Computed tomography myocardial perfusion imaging with 320-row detector computed tomography accurately detects myocardial ischemia in patients with obstructive coronary artery disease. Circ Cardiovasc Imaging 5(3):333-340.

[22] Nørgaard BL, Leipsic J, Gaur S, Seneviratne S, Ko BS, Ito H, Jensen JM, Mauri L, De Bruyne B, Bezerra H, Osawa K, Marwan M, Naber C, Erglis A, Park SJ, Christiansen EH, Kaltoft A, Lassen JF, Bøtker HE, Achenbach S (2014) Diagnostic performance of noninvasive fractional flow reserve derived from coronary computed tomography angiography in suspected coronary artery disease: the NXT trial (Analysis of Coronary Blood Flow Using CT Angiography: Next Steps). J Am Coll Cardiol 63(12):1145-1155.

[23] Nørgaard BL, Leipsic J, Koo BK, Zarins CK, Jensen JM, Sand NP, Taylor CA (2016) Coronary Computed Tomography Angiography Derived Fractional Flow Reserve and Plaque Stress. Curr Cardiovasc Imaging Rep 9:2

[24] Pontone G (2016) Anatomy and physiology in ischaemic heart disease: a second honeymoon?. Eur Heart J 37 (15):1228-1231.

[25] Gonzalez JA, Lipinski MJ, Flors L, Shaw PW, Kramer CM, Salerno M (2015) Meta-analysis of diagnostic performance of coronary computed tomography angiography, computed tomography perfusion, and computed tomography-fractional flow reserve in functional myocardial ischemia assessment versus invasive fractional flow reserve. Am J Cardiol 116(9):1469-1478.

Table 1: Baseline study characteristics

Study Name	Patient characteristics	Patients (N)	Vessels (N)	CT Used	Time between CT and invasive angiography	Type of vessels	Stress or used	CTA and CTP threshold for abnormality	CAD severity assessment	Diagnostic performance
Ko JACC 2012	Age: 62.1 + 9.9 Male: 67.5% Selection: Intermediate to high risk for CAD	40	120	320-detector	14 days	LAD LCX RCA	IV Adenosine	CTA: Stenosis >50% CTP: Visual and TPR <0.99 (we used only visual for analysis)	ICA FFR <0.8	Per-vessel and per-patient CTA+CTP, CTP and CTA
Nasis 2013	Age: 66.4+10.4 Male: 65% Selection: Suspected CAD	20	60	320-detector		LAD LCX RCA	IV Adenosine	CTA: Stenosis >50% CTP: Visual	QCA >50% and >70% stenosis and corresponding perfusion defect on SPECT-MPI	
Bamberg 2011	Age:68.1+10 Male:76% Selection: Suspected or known CAD	33	96	128 detector		LAD LCX RCA	IV Adenosine	CTA stenosis >50% CTP: visual	ICA FFR <0.75 or stenosis >85%	Per vessel and per patient CTA+CTP, CTP and CTA
Brian 2012	Age:61.5+9.9 Male:67.5 Selection: Symptomatic . with suspected CAD	40	77	320 detector	14 days	LAD LCX RCA	IV Adenosine	CTA stenosis >50% CTP: visual and TPR	ICA FFR <0.80 if >90% stenosis QCA>50% luminal stenosis	Per vessel and per patient CTA+CTP, CTP and CTA
Kim 2013	Age:65+11 Male:79% Selection: Suspected CAD	34	102	128-detector	Within 3 months (22+18 days)	LAD LCX OM RCA	IV Adenosine	CTA: >50% and CTP: Visual	QCA>50% >70% stenosis	Per vessel and per patient CTA+CTP, CTP and CTA
Choo (2013)	Age:61.7+20.5 Male:38.1	37	81	128 detector	7 days		IV Adenosine	CTA stenosis >50 %	ICA FFR <0.75	Per vessel CTA+

	Selection: low to intermediate probability CAD									CTP CTP and CTA
Bettencourt 2013	Age:62+8 Male:67% Selection: Suspected CAD	105		64 Detector	4.8 + 4.62 days	LAD LCX RCA	IV Adenosine	CTA: >50% and >70% stenosis	QCA>50% >70% stenosis	Per patient CTA+ CTP, Per vessel and per patient CTP and CTA
Reif 2013	Age: 64+10 Male:80% Selection: Clinically suspected ISR	91		320 Detector	14 days		IV adenosine	CTA: >50%	QCA>50%	Per patient CTA+ CTP CTP and CTA
Rossi (2014)	Age:60+10 Male:79 Selection: Symptomatic CAD	80	210	Dual source CT	14 days	LAD LCX RCA	IV Adenosine	CTA: >50% and >70% stenosis	FFR<0.75	Per vessel CTA+ CTP CTP and CTA
Kono (2014)	Age:62.3+9 Male:81% Selection: Suspected or known CAD	42	91			LAD LCX RCA	IV Adenosine	MBF:75.6 +22.5 MBF ratio:0.67+0.15	FFR<0.8	Per vessel CTP

TPR= Transmural perfusion ratio (Subendocardial to subepicardial contrast attenuation)

ISR: In-stent restenosis; FFR: fractional flow reserve; CAD: coronary artery disease; IV: intravenous

CT: computed tomography; CTA: computed tomography angiograpgy; CTP: Computed tomography perfusion

ICA: invasive coronary angiography; QCA: quantitative coronary angiography; MBF: myocardial blood flow

LAD: left anterior descending, LCX: circumflex, RCA: right coronary artery, OM: obtuse marginal

Fig 1 : Per Vessel CTA

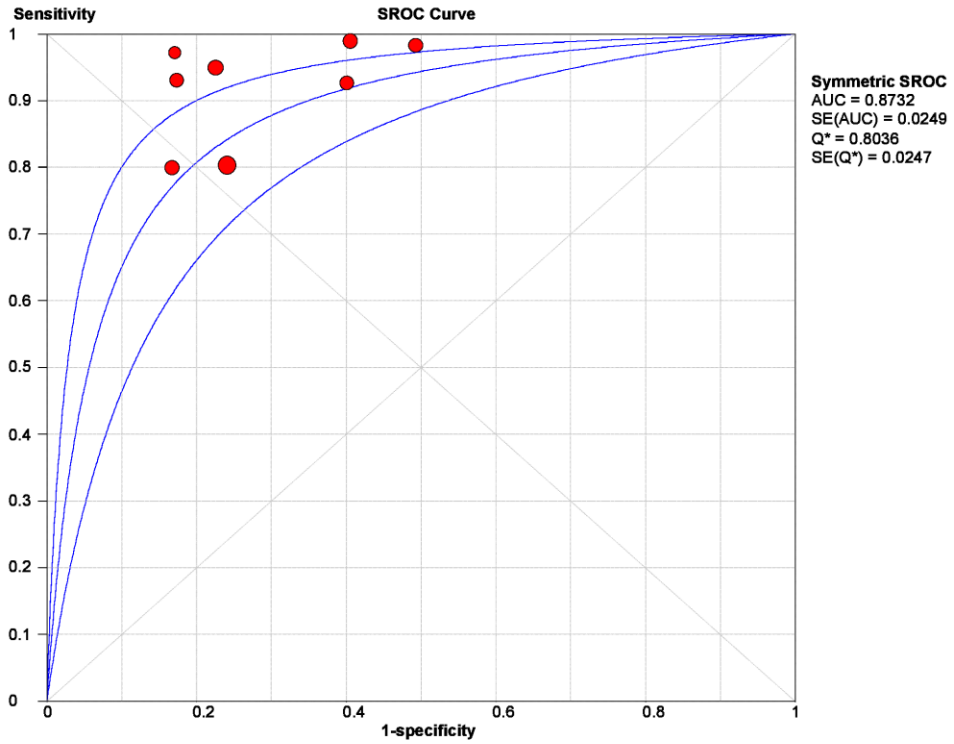

Fig 2: Per Vessel CTP

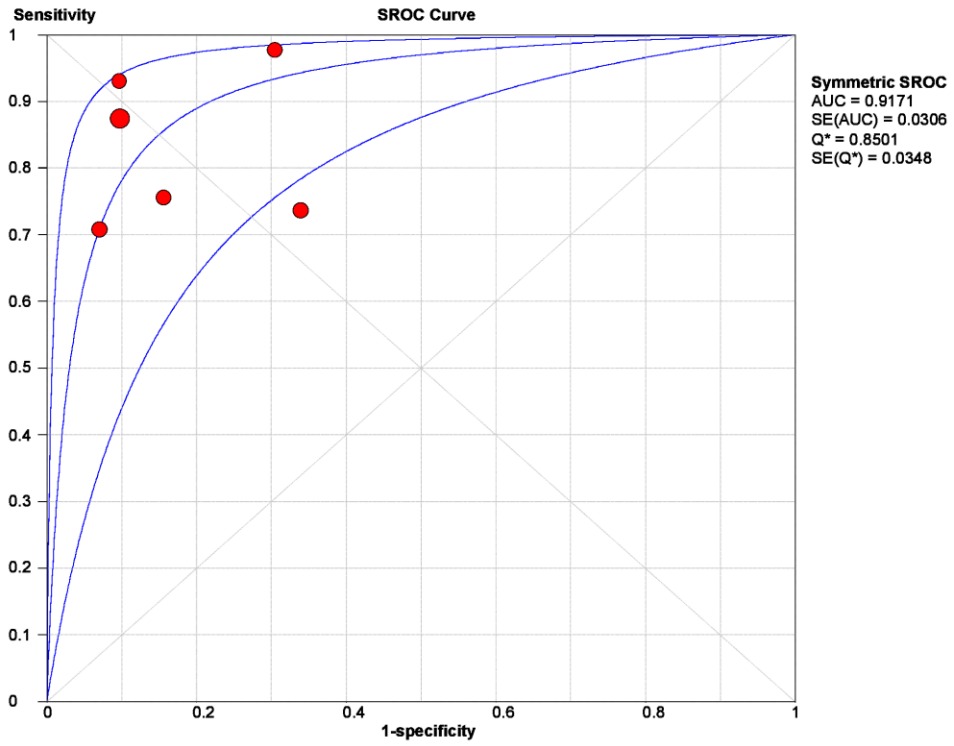

Fig 3 : Per Vessel CTA + CTP