CARDIOVASCULAR

Multivessel Revascularization on the Beating Heart by Anterolateral Left Thoracotomy

Máximo C. Guida, MD, Giuseppina Pecora, MD, Álvaro Bacalao, MD
Gustavo Muñoz, MD, Pablo Mendoza, MD, and Luís Rodríguez, MD

FundaCardio Foundation, Valencia, Venezuela

Background. Off-pump coronary artery bypass is commonly performed through a full median sternotomy; however, the tendency to reduce surgical trauma has stimulated cardiac surgeons to use less invasive techniques for single-vessel disease. The use of thoracotomy for reoperative and valvular surgery has also been reported, but its application in primary revascularization is still uncommon. We report here a series of consecutive patients who underwent complete myocardial revascularization on the beating heart through anterolateral thoracotomy–coronary artery bypass (ALT-CAB).

Methods. From November 2002 to July 2005, 255 patients (75.7% male, median age 57.9 ± 10.1 years) underwent complete revascularization using the ALT-CAB approach. Eighty-two patients (32.2%) had low ejection fraction, 145 (56.9%) previous myocardial infarct, and 215 (84.3%) multivessel disease. The mean EuroSCORE (European System for Cardiac Operative Risk Evaluation) was 3.8 and the Parsonnet score was 7.8.

Results. Complete revascularization was achieved in all patients (mean number of grafts 3.3 ± 1.0). There were no conversions to cardiopulmonary bypass, and 3 patients died (1.2%). Two hundred thirty-seven patients (93.3%) were extubated in the operating room, and 164 patients (65.1%) were discharged home within 48 hours after surgery. Two patients (0.8%) experienced a stroke and 5 (2%) needed reexploration for bleeding. There was 1 perioperative myocardial infarction (0.4%), and 14 patients (5.5%) experienced postoperative atrial fibrillation. Five patients (2%) required treatment as an outpatient for superficial wound infection, 11 (4.4%) for left pleural effusion, and 11 (4.4%) for transient phrenic nerve palsy, which resolved spontaneously. Follow-up (median, 14.6 ± 9.7 months) survival was 97.6%. One patient (0.4%), experienced a new myocardial infarction, 9 (3.6%) required new coronary angiography for recurrent of angina, and 3 of these (1.2%) underwent angioplasty.

Conclusions. Complete revascularization on the beating heart through an anterolateral thoracotomy is safe and feasible in the majority of patients requiring coronary artery surgery.

(Ann Thorac Surg 2006;81:2142–6)

Coronary artery bypass graft surgery (CABG) has been conducted for more than 30 years using cardiopulmonary bypass (CPB). In an attempt to reduce the well-known deleterious effects of CPB, off-pump coronary bypass graft (OPCABG) surgery has been proposed [1–3]. Several retrospective as well as prospective randomized studies have reported reduced morbidity when compared with conventional coronary surgery with CPB [3–6]. The advantage of the OPCABG in high-risk patients has also been demonstrated [1, 6]. To avoid some of the morbidity attributed to the use of sternotomy, which can be complicated by sternal dehiscence, mediastinitis, and prolonged recovery [1, 7, 8], several studies have been reported with good results, using anterior or posterolateral thoracotomy for single vessels, redo surgery, and more recently for complete revascularization [9–11].

We present here our experience with a consecutive unselected series of 255 patients who underwent coronary revascularization through an anterolateral thoracotomy CABG approach (ALT-CAB).

Patients and Methods

From November 2002 to July 2005, 255 consecutive patients underwent myocardial revascularization through an ALT-CAB approach. They represent 100% of the patients operated on during this time-frame. Approval was granted from the Institutional Review Board for "new surgical procedure" and for the study reported here. Consent for the operation was obtained from every patient but not for the study, as this was waived by the Institutional Review Board.

Operative Technique

After general anesthesia and selective ventilation of the right lung, the patient was positioned with the left side elevated to approximately 45 degrees. An anterolateral thoracotomy was carried out and the chest entered through the fourth or fifth intercostal space. The left internal thoracic artery (LITA) was harvested under direct vision in a skeletonized fashion using a Finocchietto retractor starting from the lower space of the incision until the origin of the first intercostal branch. In 15 cases,

Accepted for publication Jan 11, 2006.

Address correspondence to Dr Guida, Av Bolívar Norte, Resid Pecchinenda "D", Planta Baja, Valencia, Venezuela; e-mail: m120159@telcel.net.ve.

Published by Elsevier Inc

0003-4975/06/$32.00
doi:10.1016/j.athoracsur.2006.01.054

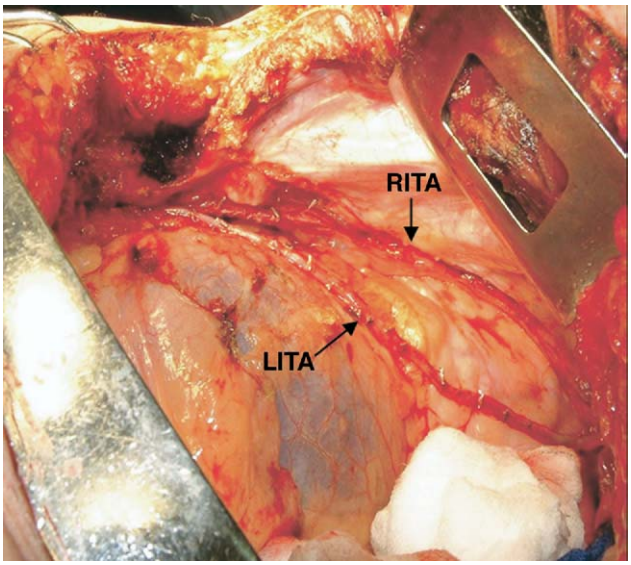

Fig 1. Left anterolateral thoracotomy. The right and left mammaries have been harvested. The pericardium is still intact. (LITA = left internal thoracic artery; RITA = right internal thoracic artery.)

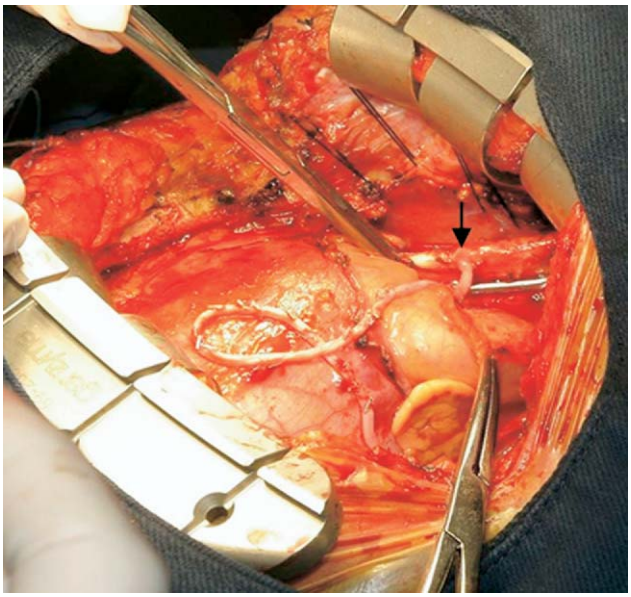

Fig 2. A side-bite exclusion clamp (arrow) has been applied to the aorta to perform the proximal vein graft anastomosis.

the right internal thoracic artery (RITA) was harvested after the pericardial fat and the thymus were carefully removed (Fig 1). The left lung was deflated in most patients. In a few patients in whom it was not possible to establish selective ventilation or who could not tolerate single lung ventilation, the left lung was gentle compressed with the use of a laparotomy sponge.

Systemic heparin, 2 mg/kg body weight, was given to maintain an activated clotting time more than 350 seconds. The LITA, and when used, the RITA were transected distally and a warm papaverine solution administered topically. The pericardium was then incised from the pulmonary artery toward the ascending aorta, and then toward the right atrial appendage. Traction sutures were positioned on the pericardium to rotate the ascending aorta to the left side. The tissue between the aorta and the pulmonary artery was dissected, and three or four further traction sutures were placed on the pulmonary adventitia to expose the lateral wall of the aorta. When proximal graft anastomosis were required (ie, saphenous vein or radial artery), these were performed first using a side-bite clamp in a conventional fashion (Fig 2).

In the event of a calcified aorta, the proximal anastomosis was performed on the descending aorta or the subclavian artery. In 8 cases (3.1%), at the beginning of our series, the Symmetry Aortic connector (St. Jude Medical Anastomosis Technology Group Inc, Minneapolis, MN) was used for proximal graft anastomosis on the aorta. In 31 patients, a composite graft was performed. To extend the pericardial incision as posterior as possible, the phrenic nerve was carefully dissected from the pericardium. The pericardium was then retracted with stay sutures to facilitate exposure of the posterior and lateral wall vessels of the heart. The distal anastomosis was performed on the beating heart using a pressure stabilizer and intracoronary shunt whenever possible. The sequence of the coronary artery anastomosis was left anterior descending first, followed by diagonal, obtuse marginal branch of circumflex, and right coronary or posterior descending last. For grafting of the left anterior descending and diagonal, no additional mobilization of the heart was required, only the table was rotated toward the right side to facilitate displacement of the heart and visualization of the vessels. For grafting the circumflex

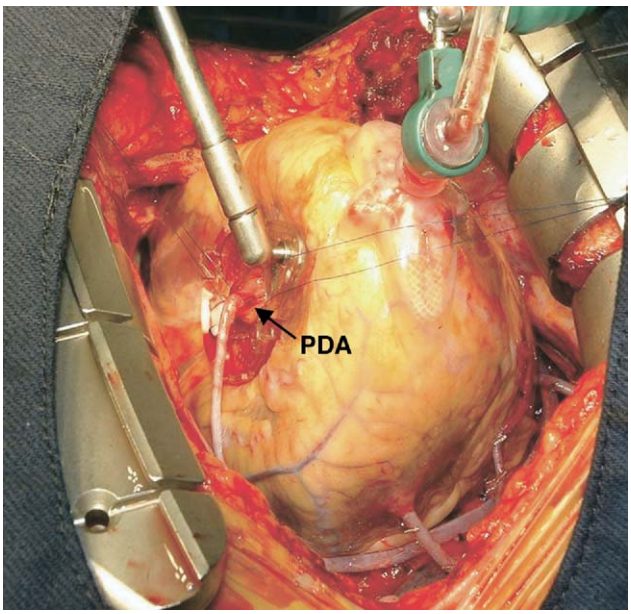

Fig 3. Grafting of the posterior descending coronary artery using an apical suction device and a pressure stabilizer. (PDA = posterior descending artery.)

and right coronary territory, the heart was lifted out of the pericardium using an apical suction device (Fig 3). At the end of the surgery, protamine was administered to achieve full heparin reversal.

To minimize postoperative incision pain, a bupivacaine solution (10/10 cc) was injected on the upper and lower side of the selected space.

At the beginning of our experience, an epidural catheter was inserted at the T5-T6 level. In the last 145 cases, a small catheter was placed through the incision and positioned in the intercostal space, to administer intermittent bupivacaine boluses for the first 36 hours; after that, pain control was achieved with nonsteroidal anti-inflammatory drugs (ibuprofen 400 mg every 8 hours or paracetemol 1 g every 6 hours). The majority of patients were extubated on the table and then transferred to the intensive care unit, where they were managed according to postoperative protocol.

On day 1 postoperative, patients were transferred to the ward under continuous cardiac telemetria monitoring. Patients and their families were trained by a member of the team how to perform respiratory exercises, how to manage the wounds, and were encouraged to mobilize and start walking as soon as possible.

We aimed to discharge patients on the second postoperative day if the routine blood tests and chest roentgenogram were normal. Once discharged home, patients were given a contact telephone number for one of the team member in case they experienced postoperatively any symptoms and complications.

Patients were then followed up with regular outpatient appointments at 1, 2, 4, 6, and 8 weeks postoperatively, at which time they were assessed by a member of the team (surgeon or cardiologist). Routine laboratory test, chest roentgenogram, and echocardiogram were also performed during the outpatient visit. Three months after the surgery, an exercise test was performed. Thereafter, patients were followed up in the outpatient clinic every 6 months.

Table 1. Patient Characteristics

Variables	Patients (n = 255)
Age (years)	57.9 ± 10.2
Sex	Male: 193 (75.7%)
	Female: 62 (24.3%)
EF	
Good > 50%	173 (67.8%)
Mild 30%–50%	68 (26.7%)
Poor < 30%	14 (5.5%)
Hypertension	240 (94.1%)
Diabetes mellitus	101 (39.6%)
Renal failure (creatinine > 200 mmol/L)	29 (11.4%)
COPD	33 (13%)
Previous MI	145 (56.9%)
Previous stroke	5 (2%)
NYHA Class	I: 40 (16.1%) II: 147 (57.3%)
	III: 53 (20.8%) IV: 15 (5.8%)
Previous PTCA	30 (11.8%)
Peripheral vascular disease	34 (13.3%)
Coronary artery disease	
One vessel	21 (8.2%)
Two vessels	19 (7.5%)
Three vessels	215 (84.3%)
Left main stem disease	42 (16.5%)
Redo	10 (4%)
EuroSCORE	3.8 ± 3.8 (range, 0–17)
Parsonnet score	7.8 ± 6.5 (range, 0–34)

Data are presented as number of observations or mean ± SD and percentage in parentheses. Original EuroSCORE and Parsonnet.

COPD = chronic obstructive pulmonary disease; EF = ejection fraction; EuroSCORE = European System for Cardiac Operative Risk Evaluation; MI = myocardial infarction; NYHA = New York Heart Association; PTCA = percutaneous transluminal coronary angiography.

Results

Two hundred and fifty-five patients underwent myocardial revascularization through an ALT-CAB during the study period. Patient characteristics are presented in Table 1. One hundred ninety-three patients were male (75.7%), and mean age was 57.9 years (range, 44 to 84). Sixty-five patients (25.5%) were older than 70 years. Mean ejection fraction was 49% ± 14%. Two hundred and fifteen patients (84.3%) had triple-vessel disease, 19 (7.5%) double-vessel disease, and 21 (8.2%) single-vessel disease. A history of previous myocardial infarction was present in 145 patients (56.9%); 40 patients (15.8%) had previous revascularization, 30 (11.8%) angioplasty and 10 (4%) surgical.

Complete revascularization was achieved in all patients. The average number of grafts was 3.3 ± 1.0. There was no conversion to on-pump or median sternotomy. Three patients died (1.2%), 1 of sudden ventricular fibrillation a few hours after the surgery and the other 2 of septic shock. Perioperative and postoperative data are presented in Table 2.

The length of intensive care unit stay was less than 24 hours for 231 patients (90%); 164 (65.1%) were discharged home within 48 hours postoperatively. Follow-up data are presented in Table 3. There were 6 late deaths (2.4%), 2 from cardiac causes. Nine patients required a new coronary angiography for recurrent angina, and 3 underwent percutaneous transluminal coronary angiography to the native coronary vessels for occlusion of venous grafts.

Comment

Coronary artery bypass grafting with cardiopulmonary bypass is a well-established and effective method of myocardial revascularization [1, 2]. However, despite advances in perfusion, anesthesia, and surgical techniques, CPB is still associated with a systemic inflammatory response that may lead to postoperative morbidity, such as bleeding, fluid retention, arrhythmias, and tem-

Table 2. Perioperative and Postoperative Data

Variables	Patients (n = 255)
Total number of grafts	720 (mean 3.3 ± 1.0 per patient)
Coronary target vessels	RCA 8
	PDA 119
	OM 169
	LAD 424
Grafts	LIMA 244
	RIMA 15
	SV 232
Composite grafts	LIMA/Radial as Y: 24 (9.4%)
	LIMA/SV as Y: 4 (1.6%)
	RIMA/LIMA as Y: 3 (1.2%)
Postoperative blood loss (mL)	593 ± 273.8
Reexploration for bleeding	5 (2%)
Extubated in operating theater	237 (93.3%)
Perioperative myocardial infarction	1 (0.4%)
Postoperative atrial fibrillation	14 (5.5%)
Postoperative stroke	2 (0.8%)
Mortality	3 (1.2%)
Length of ICU stay (hours)	
≤24	231 (90.0%)
≤48	19 (7.5%)
>72	4 (1.6%)
Discharge home postoperative day	
1	5 (2%)
2	159 (63.1%)
>3	89 (34.9%)

Data are presented as number of observations or mean ± SD and percentage in parentheses.

ICU = intensive care unit; LAD = left anterior descending artery; LIMA = left internal mammary artery; OM = obtuse marginal; PDA = posterior descending artery; RCA = right coronary artery; RIMA = right internal mammary artery; SV = saphenous vein.

porary organ dysfunction [1–3]. Coronary revascularization on the beating heart was first proposed by Benetti and colleagues [11] and Buffolo and coworkers [12] for its potential benefits of maintaining the function of major organs. In 1996, there was a revival of interest in off-pump through various means of minimal incisions, like left anterior small thoracotomy and inferior median sternotomy [9–14]. Those techniques were only applicable in the majority of cases to single-vessel revascularization. It was soon realized that the natural evolution of the technique to achieve complete coronary revascularization was by performing grafts on the beating heart through a median sternotomy.

Several retrospective as well as prospective randomized studies have provided evidence for reduced morbidity associated with off-pump surgery when compared with conventional on-pump CPB [2–6]. In particular, there is evidence of reduction of chest infection, inotropic requirement, incidence of arrhytmias, blood loss and consequent requirement for blood transfusion, intubation, and intensive care unit and hospital length of stay. At midterm follow-up, there have been no differences reported in mortality, cardiac-related events, or need for further coronary intervention between patients underwent on-pump or off-pump surgery [3, 14]. The left anterolateral thoracotomy approach (ALT-CAB) was chosen by us because potentially it offered all of the benefits of off-pump coronary revascularization, while at the same time avoiding the morbidity associated with median sternotomy. The results of our consecutive series of patients are encouraging. It is possible to perform complete revascularization in the majority of patients. The mobilization of both left and right mammaries is reasonably easy through the thoracotomy incision, and exposure and stabilization of the circumflex and posterior descending artery territory are easily achieved with minimal heart manipulation.

The majority of our patients were extubated in the operating theater, and postoperative incisional pain appeared to be reduced by the use of local anesthetics into the intercostal space, as well as more recently by the use of a catheter positioned in the wound itself, which allowed intermittent administration of boluses of bupivacaine. The incidence of atrial fibrillation was extremely low (5.5%)—a possible explanation for this is the enhanced exposure through the left thoracotomy, which reduces the need for manipulation of the heart.

We were also able to achieve a relatively early discharge from hospital, 65.1% of patients within 48 hours postoperatively. In spite of our early discharge policy, only a few patients required further treatment, in most cases as outpatients, either for superficial wound infection or presence of left pleural effusion. A small number of patients (4.4%) had transitory phrenic nerve paresia,

Table 3. Follow-Up Data[a]

Variables	Patients (n = 255)
Wound infection	Superficial: 5 (2%)
	Deep: none
Pleural effusion	11 (4.4%)
Transitory phrenic nerve paralysis	11 (4.4%)
Late mortality	Cardiac cause: 2 (0.7%)
	Noncardiac cause: 4 (1.6%)
	Total: 6 (2.4%)
Late myocardial infarction	1 (0.4%)
Coronary angiography	9 (3.6%)
PTCA	3 (1.2%) PTCA
Recurrence of angina	9 (3.6%)

[a] Follow-up (months): 14.6 ± 9.7.

Data are presented as number of observations or mean ± SD and percentage in parentheses.

PTCA = percutaneous transluminal coronary angiography.

CARDIOVASCULAR

most likely related to the dissection of the phrenic nerve from the pericardium, which we at times perform to enhance exposure. The incidence of cardiac-related events was also very low, even taking into account our relative short follow-up.

In conclusion, coronary revascularization on the beating heart through anterolateral thoracotomy is an effective and safe alternative to the median sternotomy.

We wish to thank Professor Gianni D. Angelini, Bristol Heart Institute, Bristol, United Kingdom, for helping in revising the manuscript.

References

1. Edmunds LH Jr. Extracorporeal perfusion in cardiac surgery in the adult. In Edmunds LH Jr, Ed. Cardiac surgery in the adult. McGraw-Hill, New York 1997:255–294.
2. Ascione R, Angelini GD. Off-pump coronary artery bypass surgery: the implications of the evidence. J Thorac Cardiovasc Surg 2003,125:779–81.
3. Calafiore A, Teodori G, Di Giammarco G, et al. Multiple arterial conduits without cardiopulmonary bypass: early angiographic results. Ann Thorac Surg 1999;67:450–6.
4. van Dijk D, Nierich AP, Jansen EW, et al, for the Octopus Study Group. Early outcome after off-pump versus on-pump coronary bypass surgery: results from a randomized study. Circulation 2001;104:1761–6.
5. Puskas JD, Williams WH, Duke PG, et al. Off pump coronary artery bypass grafting provides complete revascularisation with reduced myocardial injury, transfusion requirements, and length of stay: a prospective randomised comparison of two hundred unselected patients undergoing off pump versus conventional coronary artery bypass grafting. J Thorac Cardiovasc Surg 2003;125:797–808.
6. Gulielmos V, Eller M, Thiele S, et al. Influences of median sternotomy on the psychosomatic outcome in coronary artery single vessel bypass grafting. Eur J Cardiothorac Surg 1999;16(Suppl):34–8.
7. Westaby S. Surgery for coronary artery disease. In: Landmarks in cardiac surgery. Toronto: Isis Medical Media, 1997:194-8.
8. Calafiore AM, Di Giammarco G, Teodori G, et al. Left anterior descending coronary artery grafting via left anterior small thoracotomy without cardiopulmonary bypass: LAST operation. Ann Thorac Surg 1996;61:1658–65.
9. Fonger J, Doty JR, Sussman MS, Salomon NN. Lateral MIDCAB grafting via limited posterior thoracotomy. Eur J Cardiothorac Surg 1997;12:399–404.
10. Srivastava SP, Kirit NP, Skantharaja R, Barrera R, Nanayakkara D, Srivastava V. Off pump complete revascularisation through a left lateral thoracotomy (ThoraCAB): the first 200 cases. Ann Thorac Surg 2003;76:46–9.
11. Benetti FJ, Naselli G, Wood M, Geffner L. Direct myocardial revascularisation without extracorporeal circulation. Chest 1991;100:312–6.
12. Buffolo E, Andrade JCS, Branco JNR, Teles CA, Aguilar LFA, Gomez WJ. Coronary artery surgery without cardiopulmonary bypass. Ann Thorac Surg 1996;61:63–6.
13. Calafiore AM, Angelini GD. Left anterior small thoracotomy (LAST) for coronary artery revascularisation. Lancet 1996; 347:263–4.
14. Ascione R, Reeves BC, Taylor FC, Seehra HK, Angelini GD. Beating heart against cardioplegic arrest studies (BHACAS 1 and 2): quality of life at mid-term follow-up in two randomised controlled trials. Eur Heart J 2004;25:765–70.