THE ANNALS OF THORACIC SURGERY

Off-pump complete revascularization through a left lateral thoracotomy (ThoraCAB): the first 200 cases

Sudhir P. Srivastava, Kirit N. Patel, Rajaratnam Skantharaja, Reyna Barrera, Diana Nanayakkara and Vishwa Srivastava

Ann Thorac Surg 2003;76:46-49

Off-Pump Complete Revascularization Through a Left Lateral Thoracotomy (ThoraCAB): The First 200 Cases

Sudhir P. Srivastava, MD, Kirit N. Patel, MD, Rajaratnam Skantharaja, MD, Reyna Barrera, CST, Diana Nanayakkara, CCRN, and Vishwa Srivastava, BS

Cardiac Surgical Associates of West Texas, Odessa, Texas

Background. **Conventional coronary bypass surgery is associated with substantial morbidity caused by cardiopulmonary bypass (CPB) and median sternotomy. This report describes an innovative technique to perform complete revascularization through a lateral thoracotomy without CPB (thoraCAB).**

Methods. **From February 2000 to April 2001 a total of 200 patients underwent thoraCAB. The patient is positioned with the left side elevated to 45 degrees. A 5- to 6-inch incision is made over the left fourth or fifth intercostal space from just medial to the nipple to the anterior axillary line. The left internal thoracic artery is harvested as a pedicle graft under vision. Proximal anastomoses are first completed on the ascending aorta, followed by the distal coronary anastomoses on the beating heart using a stabilizer. Intercostal nerve freezing is done using a cryoprobe.**

Results. **Complete revascularization was achieved in all patients. The number of grafts averaged 2.9 ± 1.08 per patient. One patient (0.5%) died of renal failure. Two patients (1%) were converted to CPB. No strokes were observed. Three patients (1.5%) required prolonged ventilation (>48 hours). Five patients (2.5%) had postoperative bleeding requiring reexploration. Of the patients, 16 (8%) developed new-onset postoperative atrial fibrillation.**

Conclusions. **ThoraCAB has been feasible in the vast majority of patients requiring coronary bypass surgery. The prevalence of postoperative atrial fibrillation was low. Postoperative pain maybe lessened with intercostal nerve freezing.**

(Ann Thorac Surg 2003;76:46–9)

Coronary artery bypass surgery has been performed for more than 30 years using cardiopulmonary bypass (CPB) and full median sternotomy, with excellent results. Although safe and satisfactory, CPB and median sternotomy have been considered to be causes of major morbidities in cardiac surgery. Use of CPB has been associated with total body inflammatory response, microemboli, neurologic complications, excessive use of blood and blood products [1]. Median sternotomy can be complicated by sternal dehiscence, mediastinitis, prolonged pain, limitations on activities and prolonged recovery and return to normal lifestyle [1–3].

The first off-pump coronary bypass surgery was performed in 1958 [4]. Since then, off-pump approaches have been described by numerous authors [5–7]. Recently, Calafiore and associates [6], Westaby and Benetti [8], and others have reported relatively large series with excellent results. Most of these operations were performed using a full median sternotomy to gain access to all coronary arteries [6, 7, 9]. Although thoracotomy has been selectively used as an approach to the anterior and lateral coronary distributions, complete revascularization has usually required CPB and bilateral thoracotomy incisions [7, 9, 10].

Numerous studies have reported the advantages of lesser invasive approaches, which include decreased use of blood or blood products [11, 12], decreased pain [13], decreased length of hospitalization [12, 14, 15], faster recovery [3], and overall decrease in cost [12, 15, 16]. All of these advantages are applicable to the technique of complete revascularization through a left lateral thoracotomy without CPB (thoraCAB).

The present study reviews the first 200 cases of coronary artery revascularization through a left lateral thoracotomy without CPB.

Patients and Methods

From February 9, 2000 through April 2001, a total of 200 consecutive patients underwent thoraCAB. Of the patients, 24 (12%) had five grafts, 68 (34%) had four, 66 (33%) had three, 30 (15%) had two, and 12 (6.0%) had one. The average number of grafts per patient was 2.9 ± 1.08 (range 1 to 5 grafts). Arteries grafted included left anterior descending coronary artery, diagonal, ramus, obtuse marginal branches 1 through 3, right coronary artery, posterior descending

Presented at the Video Session of the Forty-eighth Annual Meeting of the Southern Thoracic Surgical Association, San Antonio, TX, Nov 8–10, 2001.

Address reprint requests to Dr Sudhir P. Srivastava, Cardiac Surgical Associates of West Texas, PA, 419 West 4th, Ste 1000, Odessa, TX 79761; e-mail: ssrivastava@msn.com.

Doctor Sudhir P. Srivastava discloses that he has a financial relationship with Medtronic, Inc.

Published by Elsevier Inc

0003-4975/03/$30.00
PII S0003-4975(03)00034-1

Table 1. Clinical Characteristics of Study Patients

Characteristic	No. (%)
Angina	195 (97.5%)
MI	70 (35%)
CHF	35 (17.5%)
CVA	6 (3%)
Carotid disease	30 (15%)
COPD	51 (25.5%)
Renal failure	14 (7%)
Diabetes	87 (43.5%)
Hypertension	160 (80%)
Smoking	147 (73.5%)
PVD	35 (17.5%)
Redo-CABG	17 (8.5%)

coronary artery, and posterolateral branch. There were 140 male and 60 female patients, with an age range of 37 to 98 years. The mean age was 64 ± 11.15 years. The ejection fraction of these patients ranged from 18% to 60%, with a mean of 51% ± 12.08%. Of the patients, 34 (17%) had an ejection fraction of 30% or less. Preoperative patient clinical characteristics are listed in Table 1.

All patients received a Swan-Ganz catheter to monitor hemodynamic indices and continuous cardiac output. Selective ventilation to the right lung was achieved using a bronchial blocker (Phycon Univent, Fuji Systems, Tokyo, Japan) in all patients. Patients were positioned with the left side elevated to approximately 45 degrees (Fig 1). Saphenous vein graft was harvested from the right lower extremity using a bridging technique. In selected young patients, the left radial artery was harvested as a pedicle. A 5- to 6-inch long incision was made over the fourth or fifth intercostal space depending on the body habitus. In male patients, the incision was made 1 inch below and 1 inch medial to the left nipple and extended laterally to the anterior axillary line. In female patients, the incision was made more laterally avoiding the submammary crease and extended to the midaxillary line. The latissimus dorsi muscle was usually spared. The left lung was selectively deflated in most patients. Five patients (2.5%) had severe chronic obstructive pulmonary disease and were unable to tolerate single lung ventilation. In these cases, a laparotomy sponge was placed over the left lung to facilitate dissection of the left internal thoracic artery (LITA). The LITA pedicle was dissected under direct vision (Fig 1). Systemic heparin, 1 to 2 mg/kg, was given. Activated clotting time measurements were performed at 20- to 30-minute intervals and maintained more than 300 seconds. The LITA was transected between clips and allowed to autodilate. A generous pericardiotomy was created obliquely from the apex of the left ventricle to the ascending aorta. Several pericardial sutures were placed to expose the ascending aorta for proximal anastomoses (Fig 2). The right pericardial sutures were placed as follows: first suture, 2 to 3 inches from the apex of the heart along the anterior edge of the pericardium; second suture, midright atrial level, 2 to 3 inches posterior and lateral (deep) to the cut edge of the pericardium; third suture, at the level of the Superior vena cava; fourth suture, at the superior most aspect of the percardiotomy, 1 inch posterior and deep to the cut edge of the pericardium. The left-sided pericardial sutures were placed as follows: first suture, in the left lower border of the pericardium; second suture, in the midportion of the pericardium; third suture, at the junction of the pericardium and pulmonary artery. All the sutures were pulled tight and secured to the retractor, bringing the ascending aorta and the right atrial appendage into view (Fig 2).

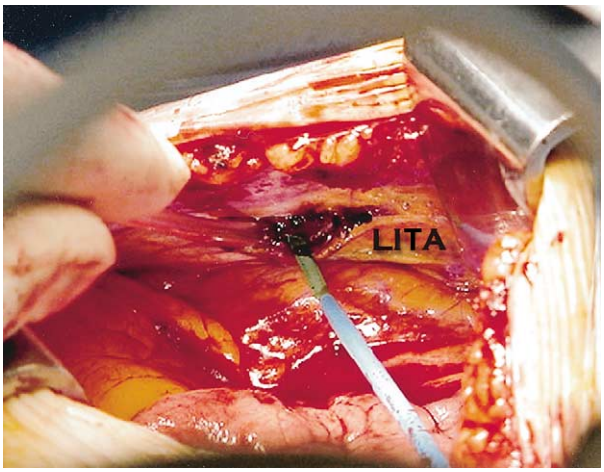

*Fig 1. Harvesting of left internal thoracic artery through the left thoracotomy approach. (*LITA = *left internal thoracic artery.)*

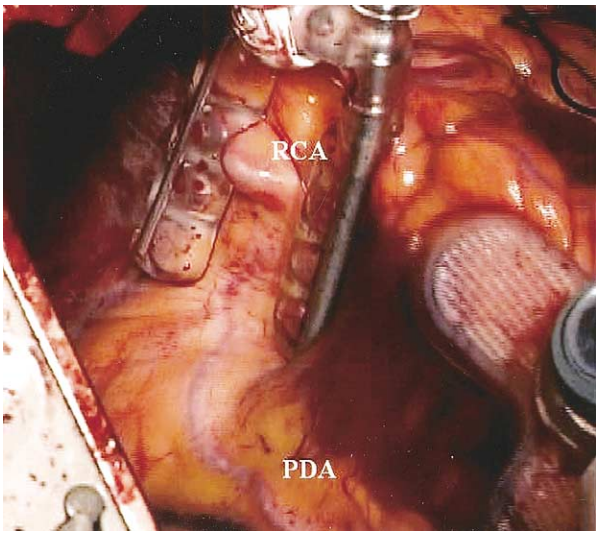

*Fig 2. Exposure and immobilization of right coronary vessels through the left thoracotomy approach. (*PDA = *posterior descending coronary artery;* RCA = *right coronary artery.)*

The proximal anastomoses were completed first. A partial occluding clamp was applied on the ascending aorta and secured with an umbilical tape to stabilize the clamp. During this time systolic blood pressure was maintained between 70 to 90 mm Hg by titrating intravenous nitroglycerin. An aortotomy was performed using a 4-mm aortic punch. Proximal anastomoses were com-

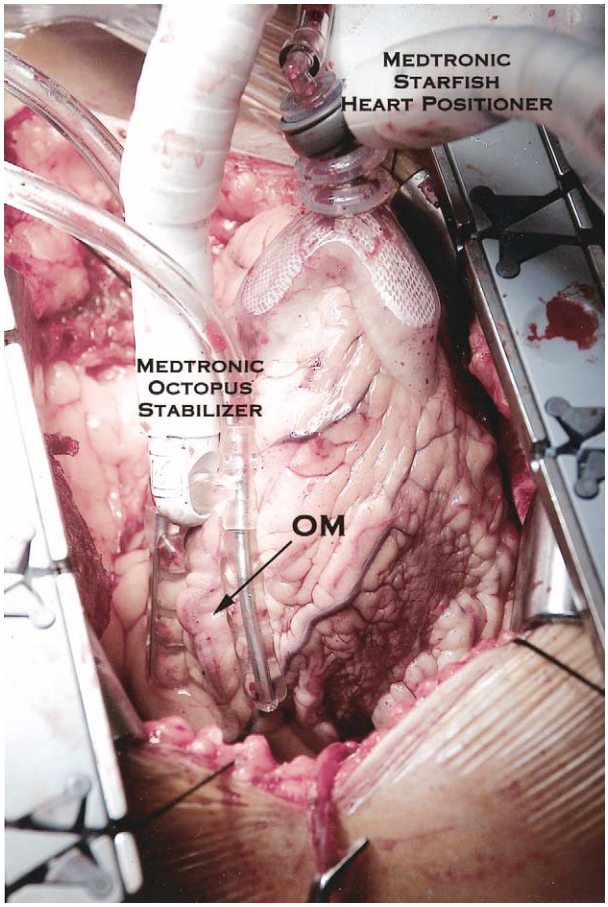

*Fig 3. Exposure and immobilization of left circumflex distribution through the left thoracotomy approach. (*OM = *obtuse marginal branch.)*

pleted using 6-0 polypropylene running suture. The anastomoses and the entire length of the conduits were thoroughly inspected for hemostasis.

The LITA was anastomosed to the left anterior descending artery left anterior descending coronary artery. The order of distal anastamoses was dictated by the coronary anatomy and myocardial function. After positioning the mechanical stabilizer (CTS/Guidant or Medtronic Octopus III stabilizer [Medtronic, Minneapolis, MN]), a 4-0 polyproplyene suture was placed deep around the proximal coronary artery and looped twice to provide proximal occlusion. A small, soft felt pledget was placed in the loop anteriorly to avoid direct contact of the Prolene (Ethicon, Somerville, NJ) suture with the coronary artery. No distal tourniquets were applied. An intracoronary shunt (Flocoil CTS/Guidant, Cupertino, CA) was reserved for patients with evidence of ischemia during tourniquet occlusion, most right coronary artery anastomoses, and impaired visualization because of excessive back bleeding. Since September 2000, nitinol vascular clips (Coalescent Surgical, Sunnyvale, CA) were used to achieve an interrupted anastomosis.

Deep pericardial suture and gauze sling were used to position the heart for optimal visualization of the lateral (Fig 3), posterior, inferior, and the distal right coronary arteries (Fig 4). To maintain hemodynamic stability, patients were placed in deep Trendelenburg position for grafting the obtuse marginal branch and the right coronary artery and its branches. A minority of patients required low-dose epinephrine and neosynephrine, which were titrated to maintain satisfactory hemodynamics.

In 16 patients (8.0%) undergoing redo CABG, limited dissection was done over the coronary arteries to be bypassed. In these cases, the proximal anastomoses were done on the descending thoracic aorta. After completion of the anastomoses, graft blood flow was measured using an ultrasonic flowmeter (Transonic, Guidant, Indianapolis, IN). Protamine was administered to achieve full heparin reversal. After placing a temporary pacing wire in the right ventricular epicardium, the pericardium and mediastinal fat was loosely approximated to cover the grafts and to prevent cardiac herniation.

In an effort to minimize postoperative incisional pain, intercostal nerve freezing was routinely performed in the posterior second through sixth intercostal spaces using a cryoprobe (Frigitronic, Shelton, CT). A single 28F angled chest tube was inserted in the left pleural cavity. In the intensive care setting ketorolac, 30 to 60 mg, was given intravenously, and 15 to 30 mg was given every 6 hours for 48 hours postoperatively in the patients with adequate renal function.

Results

One patient (0.5%) died postoperatively secondary to worsening of preexisting renal failure. Three patients (1.5%) needed prolonged mechanical ventilation for more than 48 hours. Two patients (1.0%) had conversion to cardiopulmonary bypass, which was accomplished through the same incision. In both cases direct cannulation of the right atrial appendage and the ascending aorta was achieved expeditiously for CPB; CABG was then accomplished with CPB support on the beating heart. No strokes were observed. Planned complete revasculariza-

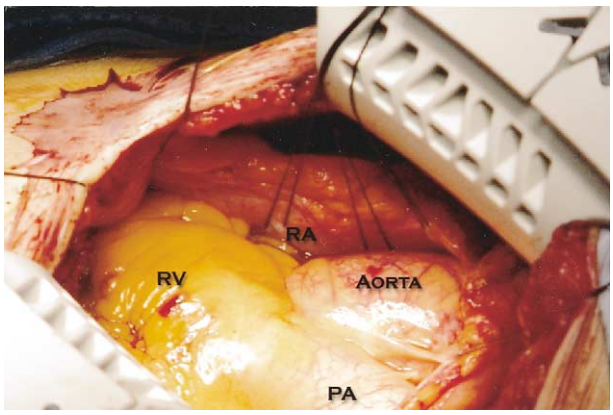

*Fig 4. Exposure of heart and great vessels after placement of pericardial sutures through the left thoracotomy approach. (*PA = *main pulmonary artery;* RA = *right atrium;* RV = *right ventricle.)*

tion was achieved in all patients. In all, 168 patients (84%) were extubated in the operating room immediately after surgery. Five patients (2.5%) required exploration for postoperative bleeding. Sixteen patients (8.0%) developed new-onset postoperative atrial fibrillation. Two patients (1.0%), both diabetic and on steroids preoperatively, were treated for superficial chest wound infection. Two patients (1.0%) experienced postoperative myocardial infarction. Two patients (1.0%) presented with pleural effusion requiring drainage within 2 weeks after discharge. Most patients did not complain of significant incisional pain after the first 24 hours of surgery. The length of hospitalization ranged from 2 to 33 days with a mean of 4.5 ± 2.8 days. Of the patients, 126 (63%) were discharged in 4 days or less.

Comment

Total revascularization without cardiopulmonary bypass continues to gain popularity with new and improved instruments and stabilizers. Recent studies have demonstrated short-term patency rates similar to conventional CABG [16, 17]. There has been reduction in postoperative length of stay, blood and blood component usage, and earlier return to normal activities. Off-pump coronary bypass performed through a full median sternotomy carries certain advantages, however this approach is associated with morbidity caused by full sternotomy. Various limited access approaches have either required CPB for complete revascularization, or the number of coronary arteries grafted has been limited. Lateral and postero-lateral thoracotomy approaches have been described for lateral and posterior vessels particularly in reoperative settings.

The left lateral thoracotomy without CPB (thoraCAB) appears to offer all of the putative benefits of off-pump CABG while avoiding the morbidity caused by median sternotomy. The prevalence of atrial fibrillation, in our series (8%) was lower than the reported incidence of 20% to 30% in conventional CABG as well as off-pump coronary artery bypass grafting. Postoperative incisional pain appears to be substantially reduced by the use of both intercostals cryothermy and intravenous ketorolac. Most of the patients can be extubated in the operating room.

As in all off-pump CABG, there is a learning curve and initial operative times are longer. Patients with extreme obesity or severe left ventricular hypertrophy with depressed ejection fraction or dilated cardiomyopathy who require grafts to all three coronary arteries may not be ideal candidates for this operation. On the other hand, patients with poor ventricular function and dilated cardiomyopathy requiring bypass to only left-sided coronary arteries appear to be excellent candidates, as exposure is better tolerated hemodynamically than is off-pump coronary artery bypass. Conversion to CPB can be achieved by cannulating the ascending aorta and right atrial appendage or pulmonary artery as the exposure and accessibility to these structures is satisfactory. Proper placement of pericardial sutures is critical for the exposure of the ascending aorta for proximal anastomoses.

Randomized controlled trials to further evaluate pain, earlier return to normal activities, and graft patency will validate the long-term efficacy of this approach.

In conclusion, the off-pump left lateral thoracotomy approach appears to be feasible in the majority of patients requiring CABG. It potentially offers an attractive and effective alternative to off-pump median sternotomy. The procedure can be accomplished safely with acceptable mortality and morbidity. Conversion to CPB can be accomplished through the same incision. There appears to be a lower incidence of atrial fibrillation. Fast in-hospital recovery and early return to normal activities may be added benefits. The addition of intercostal nerve freezing and aggressive pain management may reduce the incidence of the incisional chest pain that is generally associated with thoracotomy.

References

1. Edmunds LH Jr. Extracorporeal perfusion in cardiac surgery in the adult. In: Edmunds LH Jr, ed. Cardiac surgery in the adult. New York: McGraw-Hill, 1997:255–94.
2. Gulielmos V, Eller M, Thiele S, et al. Influence of median sternotomy on the psychosomatic outcome in coronary artery single-vessel bypass grafting. Eur J Cardio-thorac Surg 1999;16(Suppl):S34–8.
3. Westaby S. Landmarks in cardiac surgery. Toronto: Isis Medical Media, 1997:194–8.
4. Longmire W Jr, Cannon J, Kattus A. Direct-vision coronary endarterectomy for angina pectoris. N Engl J Med 259:993–9.
5. Sabiston D, Spencer F. Surgery of the chest, 6th ed. Philadelphia: WB Saunders, 1995:220–4.
6. Calafiore A, Teodori G, Di Giammarco G, et al. Multiple arterial conduits without cardiopulmonary bypass: early angiographic results. Ann Thorac Surg 1999;67(2):450–6.
7. Nader N, Khadra W, Reich N, Bacon D, Salerno T, Panos A. Blood product use in cardiac revascularization: comparison of on- and off-pump techniques. Ann Thorac Surg 1999;68:1640–3.
8. Westaby S, Benetti F. Less invasive coronary surgery: consensus from the Oxford meeting. Ann Thorac Surg 1996;62:924–31.
9. Calafiore A, Di Giammarco G, Teodori G, et al. Midterm results after minimally invasive coronary surgery. J Thorac Cardiovasc Surg 1998;115:763–71.
10. Cartier R, Blain R. Off-pump revascularization of the circumflex artery: technical aspect and short-term results. Ann Thorac Surg 1999;68:94–9.
11. Ascione R, Lloyd C, Underwood M, Lotto A, Pitsis A, Angelini G. Economic outcome of off-pump coronary artery bypass surgery: a prospective randomized study. Ann Thorac Surg 1999;68:2237–42.
12. Iaco A, Contini M, Teodori G, et al. Off or on bypass: what is the safety threshold? Ann Thorac Surg 1999;68:1486–9.
13. Zenati M, Domit T, Saul M, et al. Resource utilization for minimally invasive direct and standard coronary artery bypass grafting. Ann Thorac Surg 1997;63:S84–7.
14. Akiyama K, Ogasawara K, Inoue T, et al. Myocardial revascularization without cardiopulmonary bypass in patients with operative risk factors. Ann Thorac Surg 1999;5:31–5.
15. Del Rizzo D, Boyd W, Novick R, McKenzie F, Desai N, Menkis A. Safety and cost-effectiveness of MIDCABG in high-risk CABG patients. Ann Thorac Surg 1998;66:1002–7.
16. Mack M. Pro. Beating-heart surgery for coronary revascularization: is it the most important development since the introduction of the heart-lung machine? Ann Thorac Surg 2000;70:1774–8.
17. Contini M, Iaco A, Iovino T, et al. Current results in off pump surgery. Eur J Cardio-thorac Surg 1999;16(Suppl 1):S69–72.

Off-pump complete revascularization through a left lateral thoracotomy (ThoraCAB): the first 200 cases

Sudhir P. Srivastava, Kirit N. Patel, Rajaratnam Skantharaja, Reyna Barrera, Diana Nanayakkara and Vishwa Srivastava

Ann Thorac Surg 2003;76:46-49